

Stridor/Snoring/OSAS

Dr Karen Lehmann

Division of Otorhinolaryngology
University of Stellenbosch and Tygerberg Hospital



Stridor/Stertor

- Auditory manifestations of disordered respiratory function – ie noisy breathing resulting from an upper airway obstruction
- Merit investigation in every case

Introduction

- Stertor
 - Caused by obstruction of airway above the larynx
 - Vibration in tissues of nasopharynx, oropharynx or soft palate
- Stridor
 - Due to airflow changes in the larynx, trachea or bronchi

Associated signs and symptoms

- Dyspnoea
 - Severity of one reflects severity of the other
 - Signs of respiratory embarrassment
 - Nasal flaring
 - Accessory muscles
 - Cyanosis
 - Indrawing of soft tissues
 - Tracheal tug
 - Beware of signs in neonate and small infant

Associated signs and symptoms *(continued)*

- Cough
 - Harsh and barking
 - Subglottic inflammation/tracheal compression
- Hoarseness
 - Speech or crying
 - Vocal cord pathology

Associated signs and symptoms *(continued)*

- Deglutition and respiration
 - Share common pathway: oropharynx
 - Disorders of the one may interfere with the other
 - Stridor/Stertor often increase during feeding
 - Infants often noted to be poor or slow feeders

General features: Stridor

- Always a symptom or a sign; never a diagnosis or a disease
- History and physical examination will indicate problem areas
- Endoscopy will confirm final diagnosis

History and physical examination

- Character
 - Wheezing, snoring, croaking etc
 - Continuous or intermittent
 - Features of obstructed breathing severity (loudness)
- Age at onset: congenital could present later
- Relationship to feeding, crying and exercise
- Related diseases (cardiac, respiratory, neurologic)
- Previous endotracheal intubation or prolonged ventilation

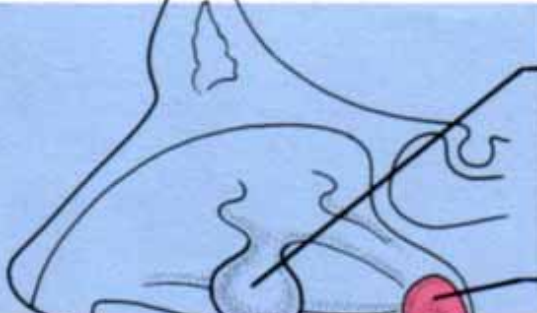
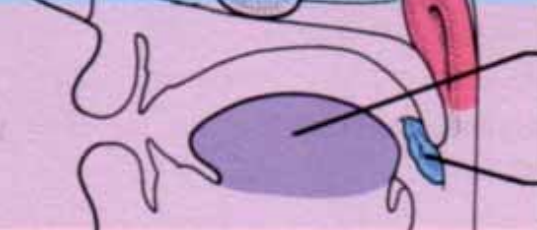

History and physical examination *(continued)*

- Onset
 - Rapid (trauma, upper respiratory tract infection)
 - Slowly progressive (neoplastic cause)
- Snoring at night, daytime mouth breathing, daytime somnolence (OSAS)

History and physical examination *(continued)*

- General
 - Alert, awake
 - Pattern of breathing
 - Congenital disorders

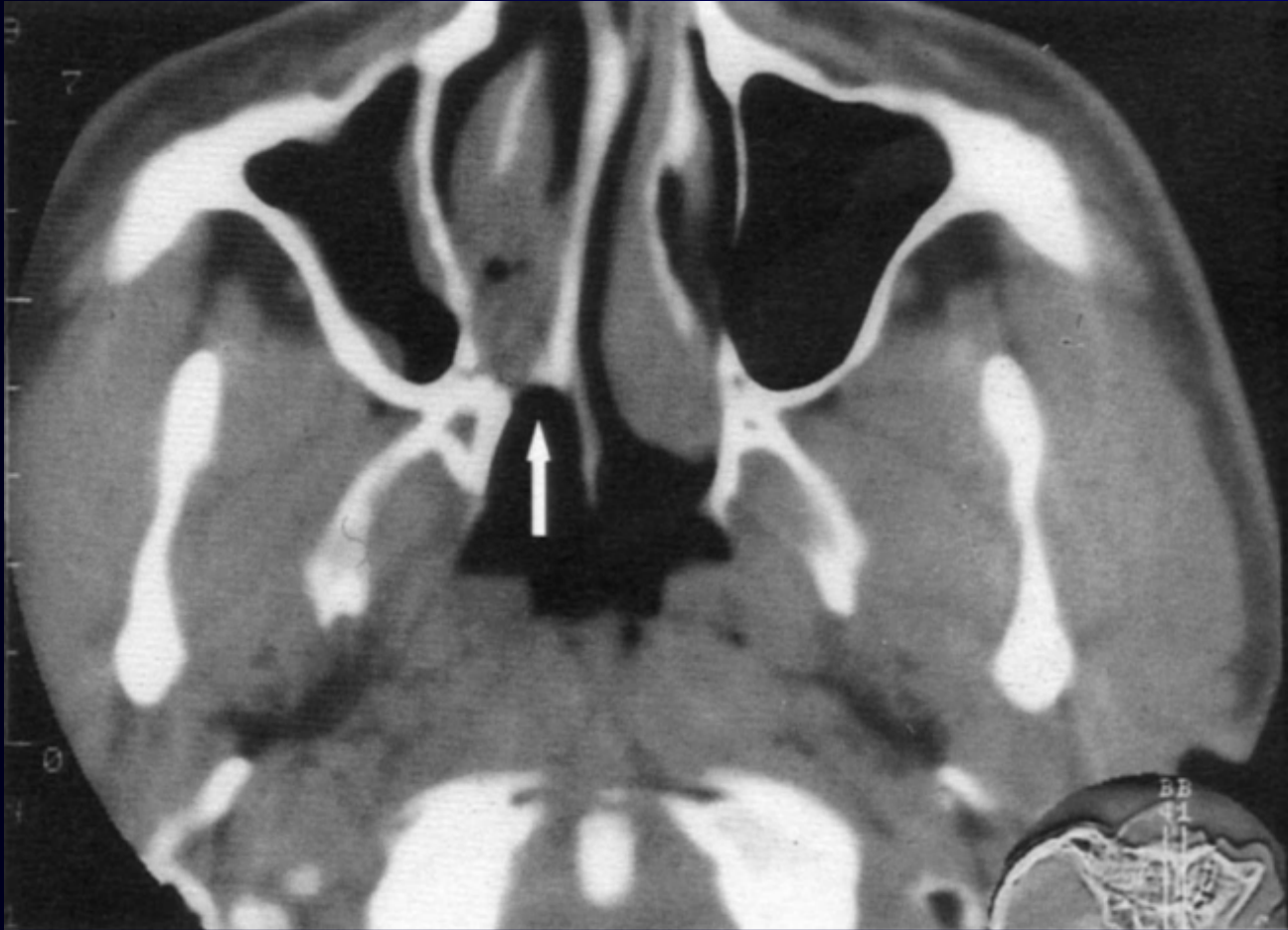History and physical examination *(continued)*

Sites of obstruction		Causes of obstruction
Nose/nasopharynx		Nasal polyps Grossly deflected nasal septum Adenoids
Oropharynx/velopharynx		Macroglossia (absolute or relative) Soft palate Tonsils
Laryngotrachea		Obstructive lesions (e.g. tumour, cysts)

History and physical examination *(continued)*

- Nose and oral cavity
 - Septal deviation
 - Hematoma, abscess
 - Malignancy
 - Polyps
 - Rhinitis (chronic, allergic)
 - Choanal atresia
 - Post nasal drip, mucus on upper lip

History and physical examination *(continued)*



History and physical examination *(continued)*

- Mandible
 - Micrognathia
 - Retrognathia
- Nutritional status
 - Obesity
 - Failure to thrive
- Auscultation and palpation
 - Neck mass

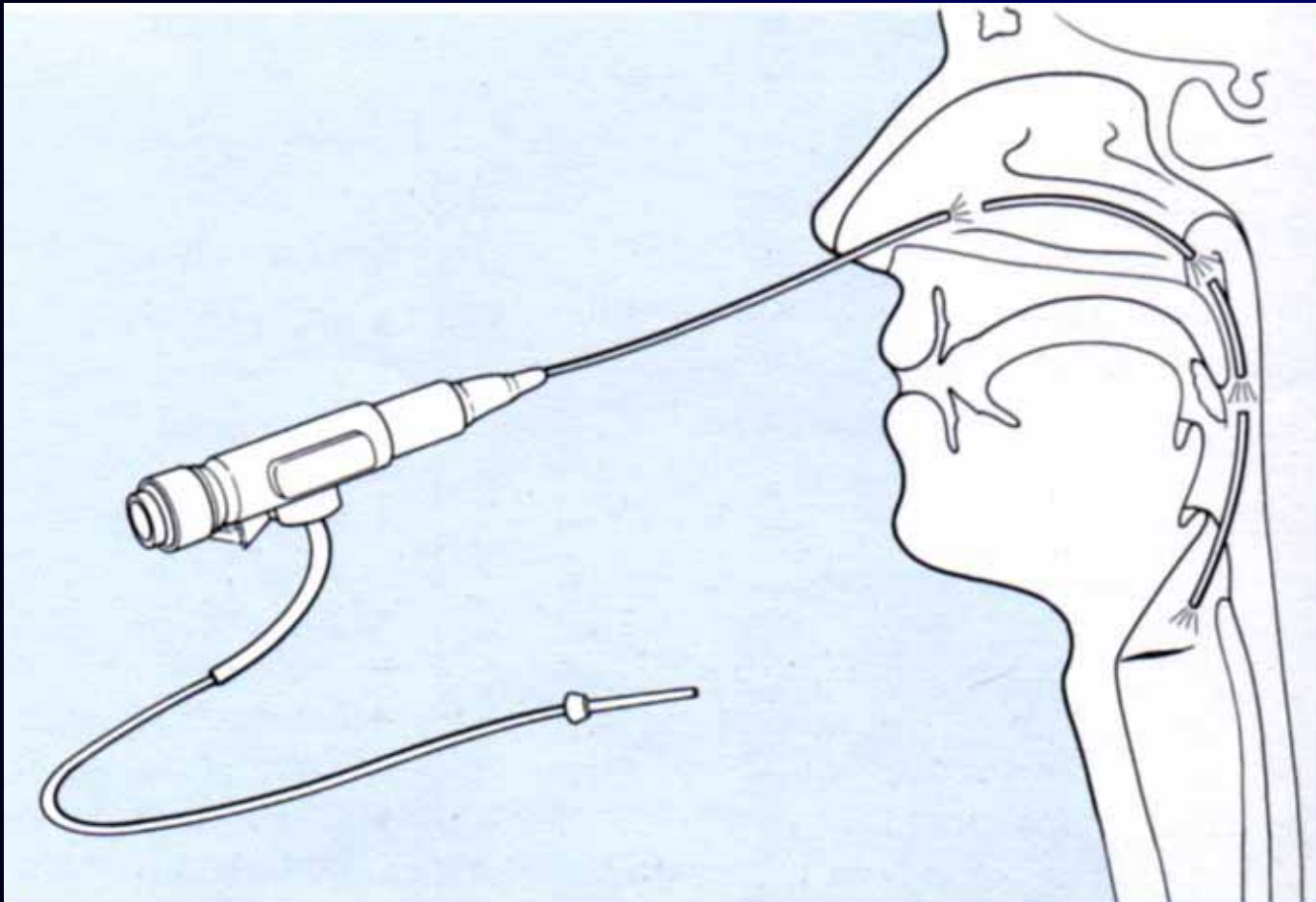
Special investigations

- Related organ systems
 - Cardiovascular (RHF)
 - Respiratory
 - Neurological
- Arterial blood gas levels
- Oxygen sensor (saturation)
- Radiology
 - Lateral soft tissue X-ray neck
 - Tomography, angiography
 - CT/MRE

Special investigations *(continued)*

- Endoscopy
 - Gold standard
- Evaluate nasal passages, nasopharynx, oropharynx, larynx and trachea
- General anaesthetic if required
- Decide on treatment

Special investigations *(continued)*



Causes and classification

- Adult
- Children
- Neonatal

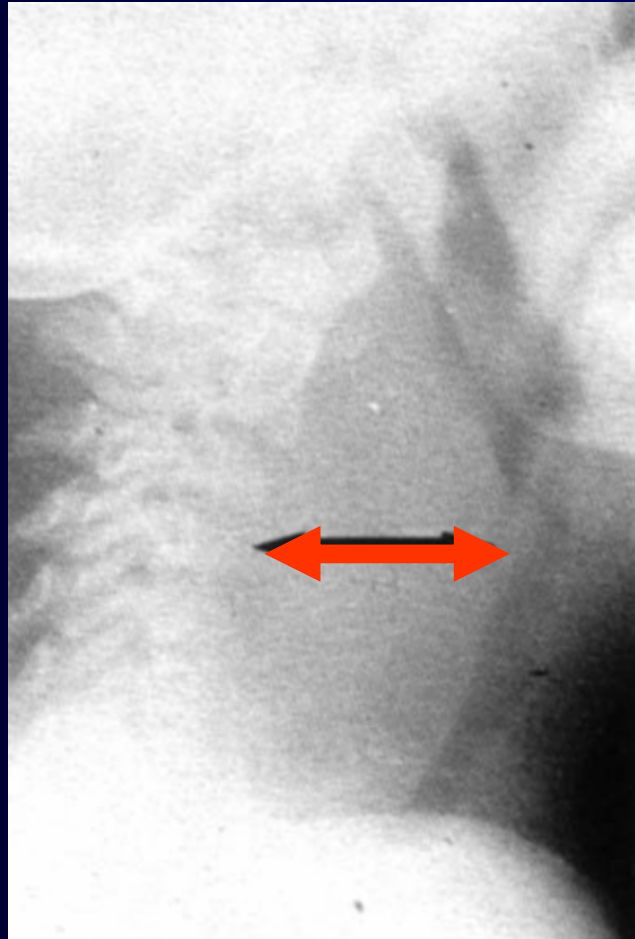
Causes: Adult

- Malignancy
 - Nasopharynx, oropharynx, larynx
- Laryngeal trauma
 - post intubation
- Acute laryngitis
- Supraglottitis/epiglottitis

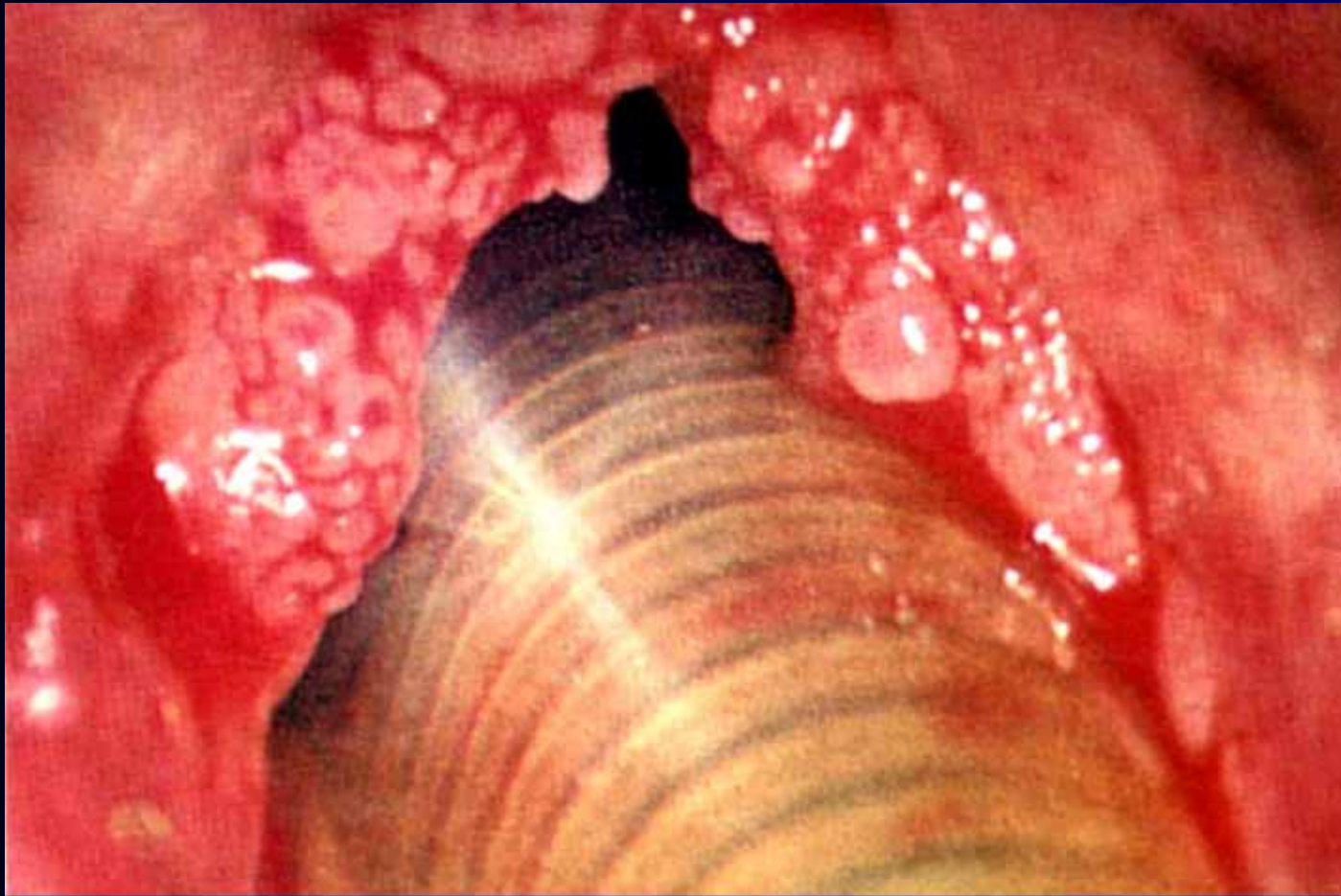
Causes: Children *(continued)*

- Laryngotracheobronchitis (Croup)
- Epiglottitis
- Foreign body
- Trauma
 - Post intubation
- Retropharyngeal abscess
- Laryngeal papillomata

Causes: Children *(continued)*



Causes: Children *(continued)*



Causes: Neonatal

- Laryngomalacia
- Congenital tumors, cysts
- Webs
- Subglottic stenosis
- Vocal cord paralysis

Causes: Examples

- Laryngotracheobronchitis (Croup)
 - Viral infection
 - 6 months - 3 years
 - Pyrexia, barking cough
 - Stridor: Grade I-IV
- Treatment
 - Hospitalisation
 - Oxygen and adrenaline nebulisation
 - Intubation in severe cases

Causes: Examples *(continued)*

- Epiglottitis
 - Haemophilus influenza Group B
 - 3 years - 7 years
 - Pyrexia, severe sore throat
 - Stridor
 - Dribbling, breathing with raised chin, open mouth
 - Cherry red epiglottitis

Causes: Examples *(continued)*

- Treatment
 - Emergency
 - IVI antibiotics
 - Needs intubation
 - Small tube
 - Extubation within 48 hours

Causes: Examples *(continued)*

- Laryngomalacia
 - Weak supraglottic framework
 - Self-limiting; resolves at 3 years
- Subglottic stenosis
 - Congenital or acquired
 - Beware after intubation
 - May need tracheostomy

Causes: Examples *(continued)*

- Malignancy
 - Usually slow in onset
 - Progressive
 - Associated symptoms
 - Hoarseness
 - Dysphagia/odynophagia
 - Associated signs
 - Neck mass

Obstructive sleep apnoea syndrome (OSAS)

- Definitions
 - Apnoea
 - Cessation of airflow at nostrils for 10 seconds or longer
 - Apnoea index
 - Number of apnoeas per hour of sleep
 - Hypopnoea
 - Reduction in airflow associated with desaturation
 - Sleep apnoea syndrome
 - 30 or more apnoeic episodes during a 7-hour sleep

Causes of OSAS

- Nose
 - Polyps
 - Deviated nasal septum
- Pharynx
 - Adenoidal hypertrophy
 - Nasopharyngeal tumor
 - Large palatine/lingual tonsils
 - Retropharyngeal mass
 - Large tongue
 - Obesity

Clinical features

- Frequent wakening and disturbed sleep pattern
- Snoring
 - Sign of partial airway obstruction
- Apnoeic episodes
- Daytime somnolence

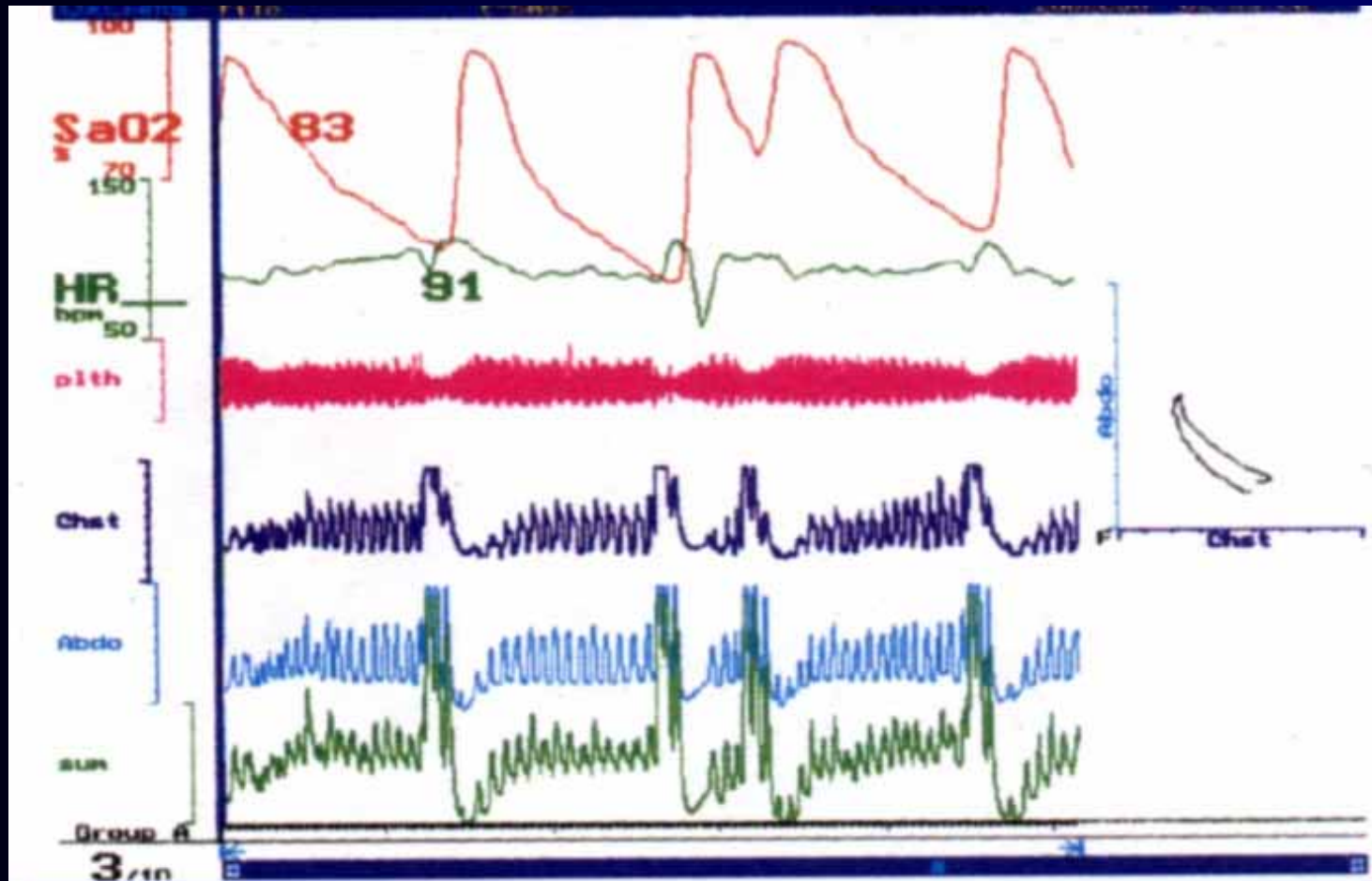
Signs of obstructive sleep apnoea

- Poor nasal airway
- Mouth breathing
- Noisy respiration
- Grossly hypertrophic tonsils
- Short, thick neck
- Obesity
- Complications of OSAS:
 - Pulmonary hypertension, RHF, COR pulmonale

Special investigations

- Sleep studies/
polysomnography
- Lateral X-ray
neck
- CXR, ECG
- Nasendoscopy
- Elective
intubation

Special investigations *(continued)*



Treatment (OSAS)

- Conservative
 - Dietary modification
 - Nasopharyngeal airway
 - CPAP (continuous positive airway pressure)
- Surgical
 - Adenotonsillectomy
 - UPPP
 - Tracheostomy

Summary

- Stridor is abnormal and should be investigated
- Laryngeal evaluation has to be performed in all patients with stridor
- Snoring for longer than 6 months in a child is abnormal

