

Facial nerve (CN7) palsy

- Shameemah Allie
- Natasha Bailey
- Eulalie Burger
- Sharon de Kock
- Liaquat Parker
- Stacey Rossouw

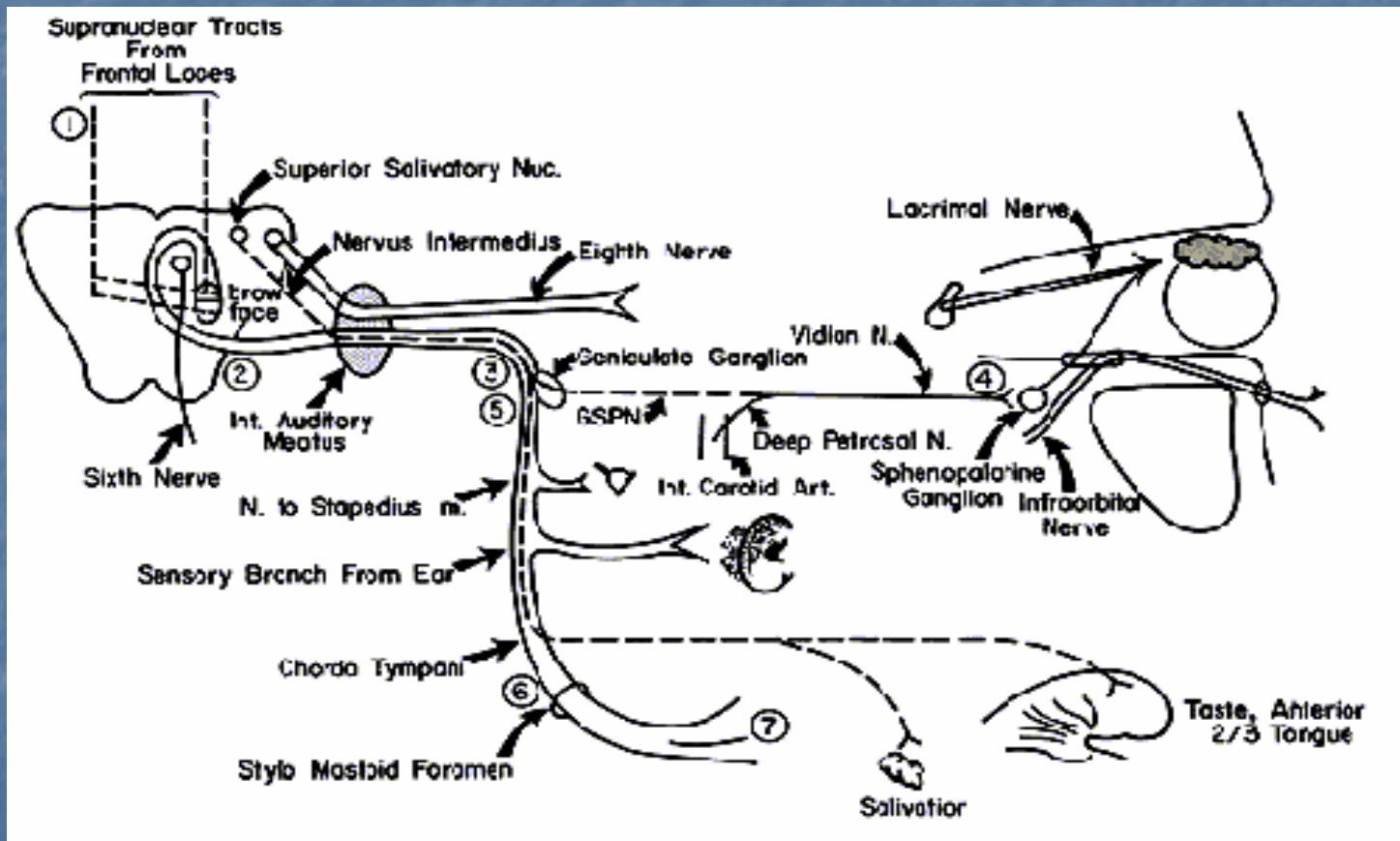
Anatomy

- Intracranial portion
- Meatal portion
- Intratemporal portion
 - Labyrinthine segment
 - Tympanic segment
 - Mastoid segment
- Extracranial portion
- Various anomalous courses exist, and these are more common in malformation of the ear.

Anatomy cont.

- The facial nerve contains myelinated fibers which innervate the muscles of facial expression, the stapedius muscle, the postauricular muscles, the posterior belly of the digastric muscle, and the platysma. The remaining fibers form the nervus intermedius contains sensory fibers (taste) from the anterior 2/3 of the tongue, and parasympathetic secretomotor fibers to the parotid, submandibular, sublingual, and lacrimal gland. The facial nerve also contains a few general somatic afferent fibers which join the auricular branch of the vagus to supply sensation to the external auditory meatus, and visceral afferents which innervate the mucous membranes of the nose, palate, and pharynx via the greater palatine nerve.
- The motor nucleus of the facial nerve lies deep within the reticular formation of the pons where it receives input from the precentral gyrus of the motor cortex, which innervates the ipsilateral and contralateral forehead. The cerebral cortical tracts also innervate the contralateral portion of the remaining face. This accounts for the sparing of the forehead motion in supranuclear lesions of the facial nerve.

Course of the Facial nerve



Pathophysiology

- The degree of nerve injury is graded according to Sunderland's classification.
- According to this classification there are 5 degrees of nerve injury namely:
 - Neuropraxia (1st degree)
 - Axonotmesis (2nd degree)
 - Endoneurotmesis (3rd degree)
 - Perineurotmesis (4th degree)
 - Neurotmesis (5th degree)

Pathophysiology cont.

- Degeneration:
 - Interruption of the continuity of the axon separates the distal axon from its metabolic source, the neuron or cell body. Wallerian degeneration of the distal axon and myelin sheath begins within 24 hours.
 - Macrophages phagocytose degraded myelin and axons.
- Regeneration:
 - Regeneration is possible, but sometimes with complications:
 - Simple misdirection: the entry of one axon into a tubule destined for a muscle other than the one previously innervated. Clinical expression: synkinesis or associated movement.
 - Complex misdirection: a single axon through branching innervates tubules to different muscles. Clinical expression: mass movement.
 - Other sequelae of faulty regeneration: tics, spasms, contractures, weakness, and gustatory lacrimation.

Causes:

- Idiopathic/Bell's palsy
- Trauma
- Infections
- Tumours
- Congenital
- Systemic/Metabolic

Evaluation

- Clinically
- Electrodiagnostic testing
 - Nerve excitability test
 - Electroneurography
- Topographic testing
- Other diagnostic tests:
 - Audiometry
 - Radiology

Clinical evaluation

- The first step in evaluating any patient who presents with facial nerve paralysis involves taking a careful and thorough history. It is important to determine the onset of the paralysis (sudden vs. delayed), the duration, and the rate of progression. It is especially important to determine whether the paralysis is complete versus incomplete. Patients should be questioned regarding previous episodes, family history, associated symptoms (hearing loss, otorrhoea, otalgia, vertigo, headaches, blurred vision, parasthesias), associated medical illnesses (diabetes, pregnancy, autoimmune disorders, cancer), history of trauma (recent or remote), and previous surgery (otologic, rhytidectomy, parotidectomy).
- A complete head and neck examination must be performed, including microscopic examination of the ears, careful palpation of the parotid glands and neck, ophthalmologic examination (papilloedema), auscultation of the neck (carotid bruits), and a thorough neurological examination.
- It is also important to determine if the paralysis is central or peripheral.

Clinical evaluation cont.

- The presence of a peripheral facial paralysis demands a complete head and neck examination with otoscopy and cranial nerve evaluation.
- Characteristics of a peripheral paralysis:
 - At rest: less prominent wrinkles on forehead of affected side, eyebrow droop, flattened nasolabial fold, corner of mouth turned down.
 - Unable to wrinkle forehead, raise eyebrow, wrinkle nasolabial fold, purse lips, show teeth, or completely close eye.
 - Bell phenomenon: visible vertical rotation of globe on closing affected eye.
- Characteristics of a central facial paralysis:
 - Because of uncrossed contributions from ipsilateral supranuclear areas, movements of the frontal and upper orbicularis oculi mm. tend to be spared.
 - Facial movement may be present on affected side during emotional expression.
 - Involvement of tongue.
 - Presence of lacrimation and salivation.

Management

- Treatment of facial paralysis is dependant on the cause.
- Immediate management includes:
 - adequate eye protection (tears/patch)
 - exclude obvious cause
 - initiate appropriate therapy
 - seek ENT referral.

Specific Treatment: Bell's palsy

- Most recover spontaneously.
- Steroids promote earlier recovery, decrease pain and reduce effects.
- Assess patient after 5 days and continue steroids as necessary.
- ? New evidence showing that Acyclovir decreases neural degeneration.

Trauma:

- Important to ascertain whether onset of palsy was immediate or delayed.
- Do a full clinical examination and a CT scan can be obtained to assess the bone and the nerve.
- Usually with immediate complete paralysis, surgical exploration and repair is performed and with incomplete or delayed onset paralysis, facial nerve testing is performed and treated according to findings.

Infection:

- Herpes zoster
 - Acyclovir plus analgesia
- Acute otitis media
 - Myringotomy plus antibiotics
- Chronic otitis media
 - Mastoidectomy plus facial n. exploration and decompression
- Tuberculosis
 - Anti-TB treatment
- Malignant otitis externa
 - IV antibiotics (piperacillin, amikacin and metronidazole)

Tumours:

- Treatment is dependant on the location, extent and malignant potential of the tumour.
- Don't confuse with a Bell's palsy, look for:
 - a slowly evolving facial paresis
 - facial twitching
 - a middle ear mass
 - conductive deafness.

In Summary:

- Bell's palsy is the commonest cause of a facial palsy, followed by trauma. However, other conditions need to be excluded.
- All patients with facial n. palsies require a full head and neck examination as well as appropriate special investigations.
- Immediate management includes:
 - adequate eye protection (tears/patch)
 - exclude obvious cause
 - initiate appropriate therapy
 - seek ENT referral.

References:

- Department notes
- CME – May 2004
- <http://www.medscape.com>
- <http://www.bcm.edu/oto/page.html>