

FLUID IN THE MIDDLE EAR: O.M.E.

James Loock
Division Otorhinolaryngology
Faculty of Health Sciences
Tygerberg Campus
University of Stellenbosch

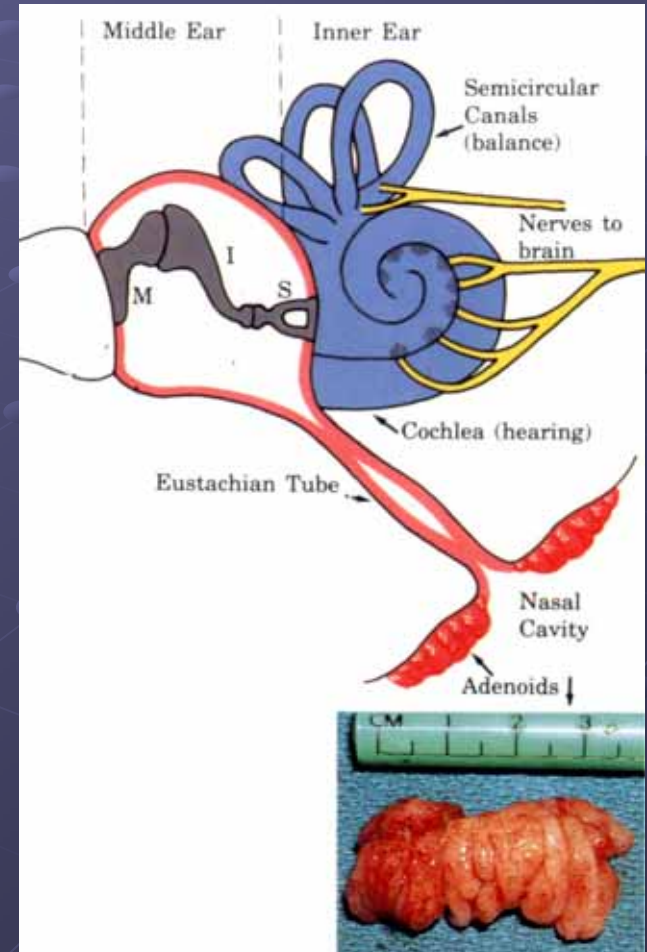


WHAT IS OME?: OME PSEUDONYMS:

- OTITIS MEDIA WITH EFFUSION
- MIDDLE EAR EFFUSION
- “GLUE EARS”
- SEROUS OTITIS MEDIA
- SECRETORY OTITIS MEDIA
- CATARRHAL OTITIS MEDIA

Aeration/ventilation of the middle ear:

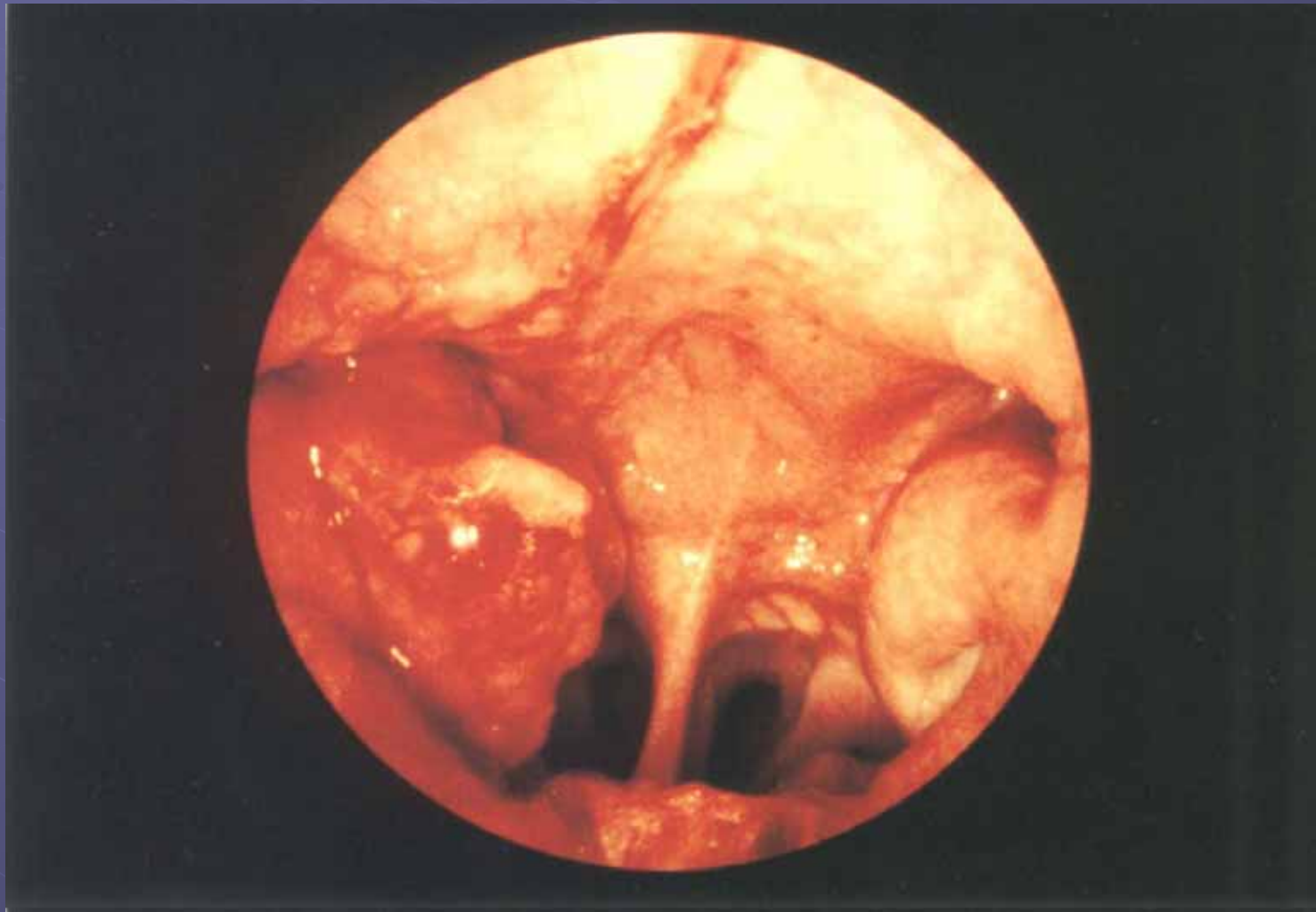
- Need for air supply
- Role of E.T.
- Role of mastoid air cells



Causes of E.T. dysfunction:

- Children: “normal”
- Children with very high incidence:
 - Cleft palate
 - Down’s
- Adults: be suspicious:
 - URTI
 - Sinusitis
 - Nasopharyngeal carcinoma
 - Radiotherapy

Nasopharyngeal carcinoma:



Clinical presentation OME:

HISTORY:

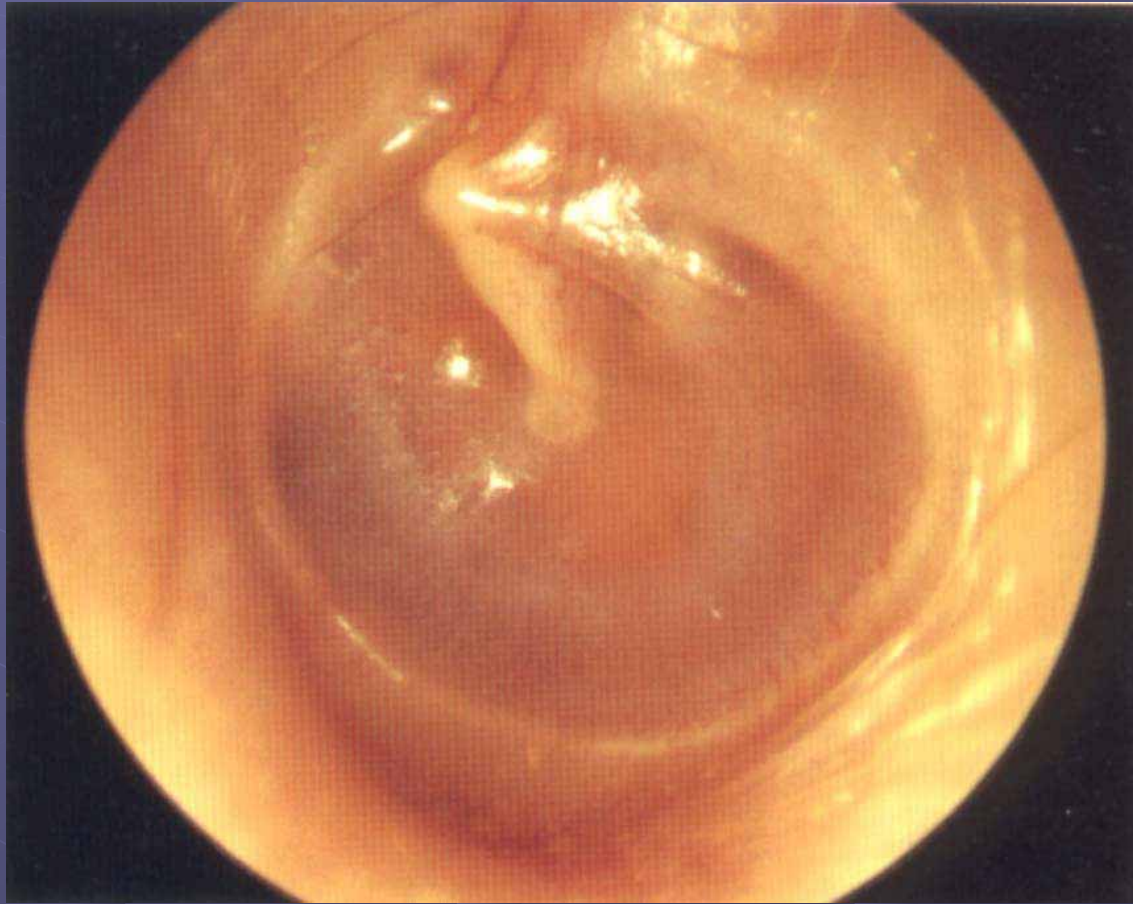
- “Silent” in children
- Moderate conductive hearing loss
- Pulling on ears
- ?Dysequilibrium
- Adults complain bitterly of “blocked” feeling

Clinical presentation OME:

EXAMINATION:

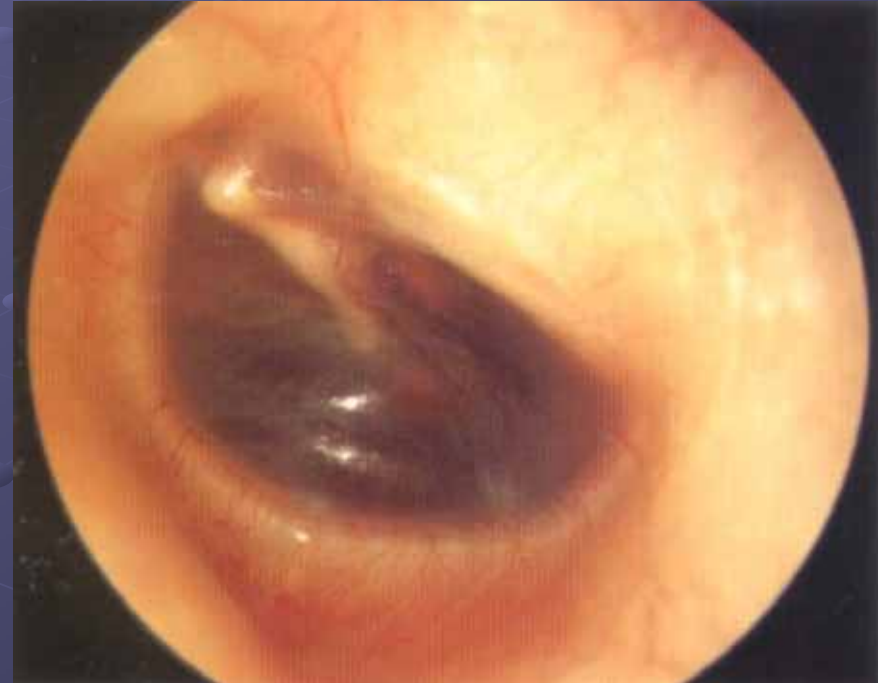
- Difficult to see, subtle!
- ? “The most difficult otoscopic diagnosis!”
- Difficulties of examining a child
- Importance of NOT making the child cry!
- Getting your equipment right
- Pneumatic otoscopy
- Tympanometry

Signs of OME:



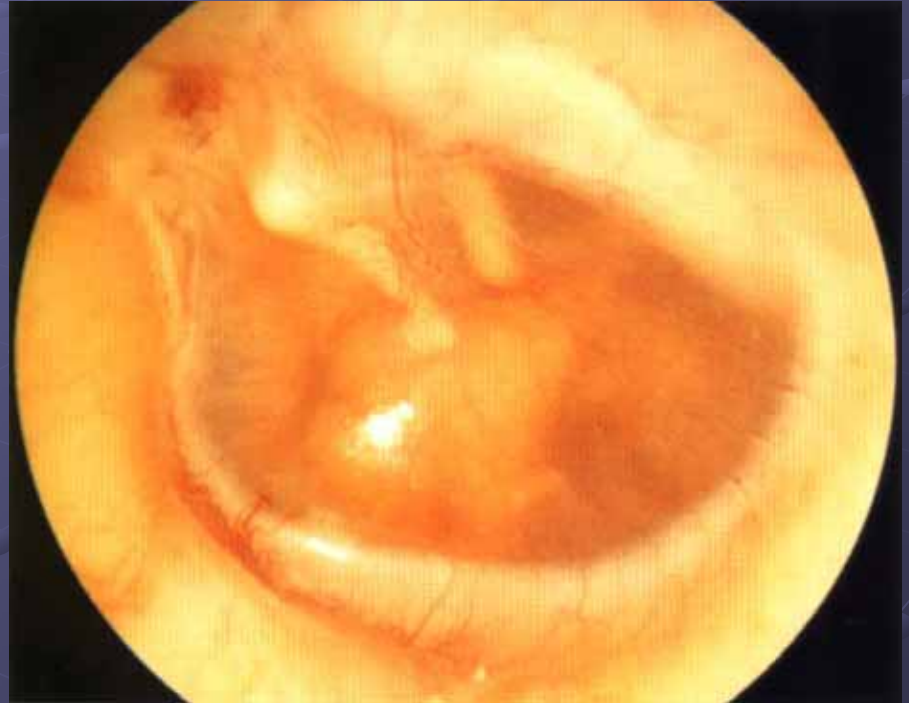Signs of OME:

- Discoloured fluid behind T.M
- TM retracted



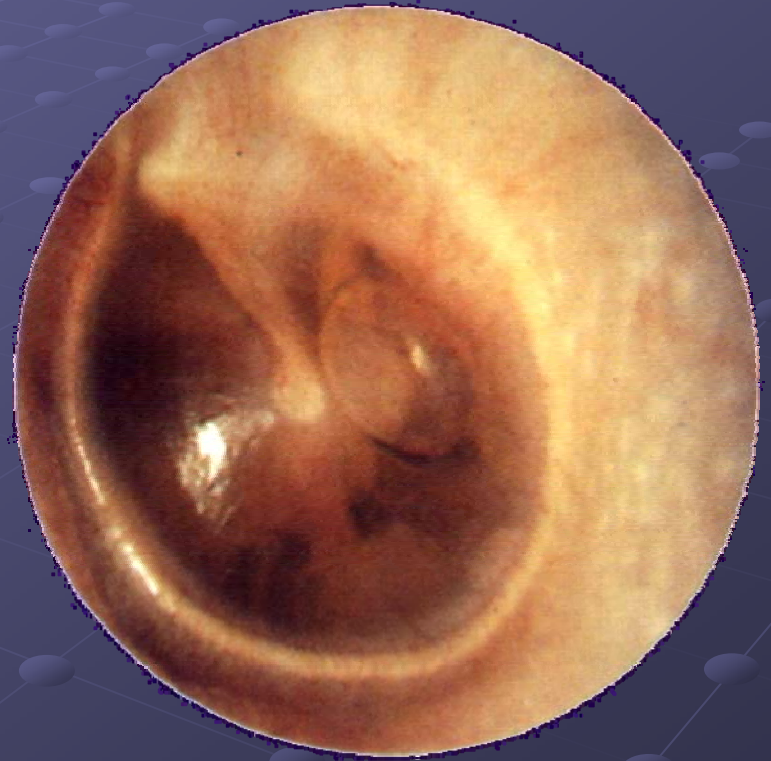
Signs of OME:

- Discoloured fluid behind T.M
- TM retracted



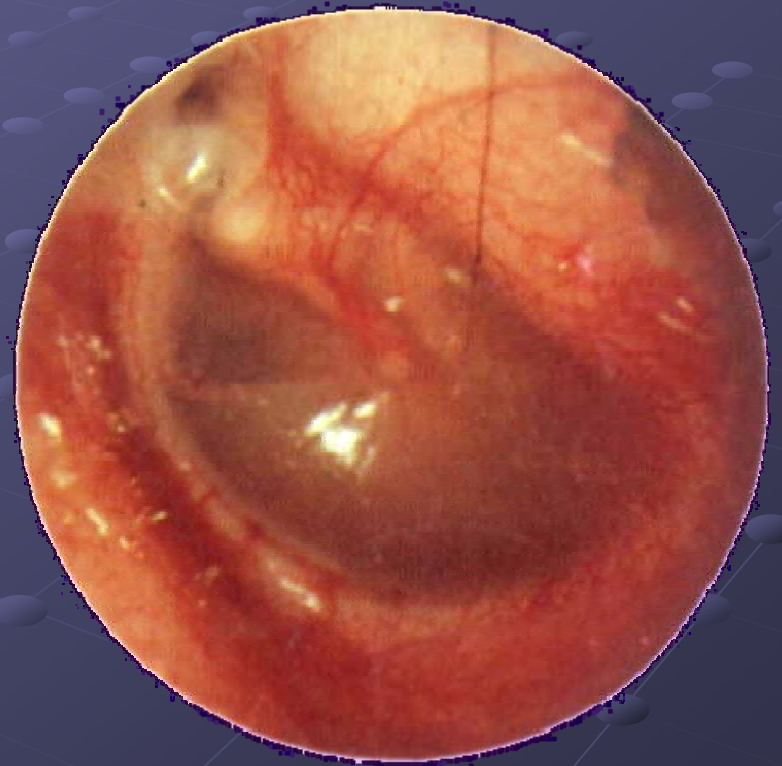
Signs of OME:

- Air bubble in ME fluid

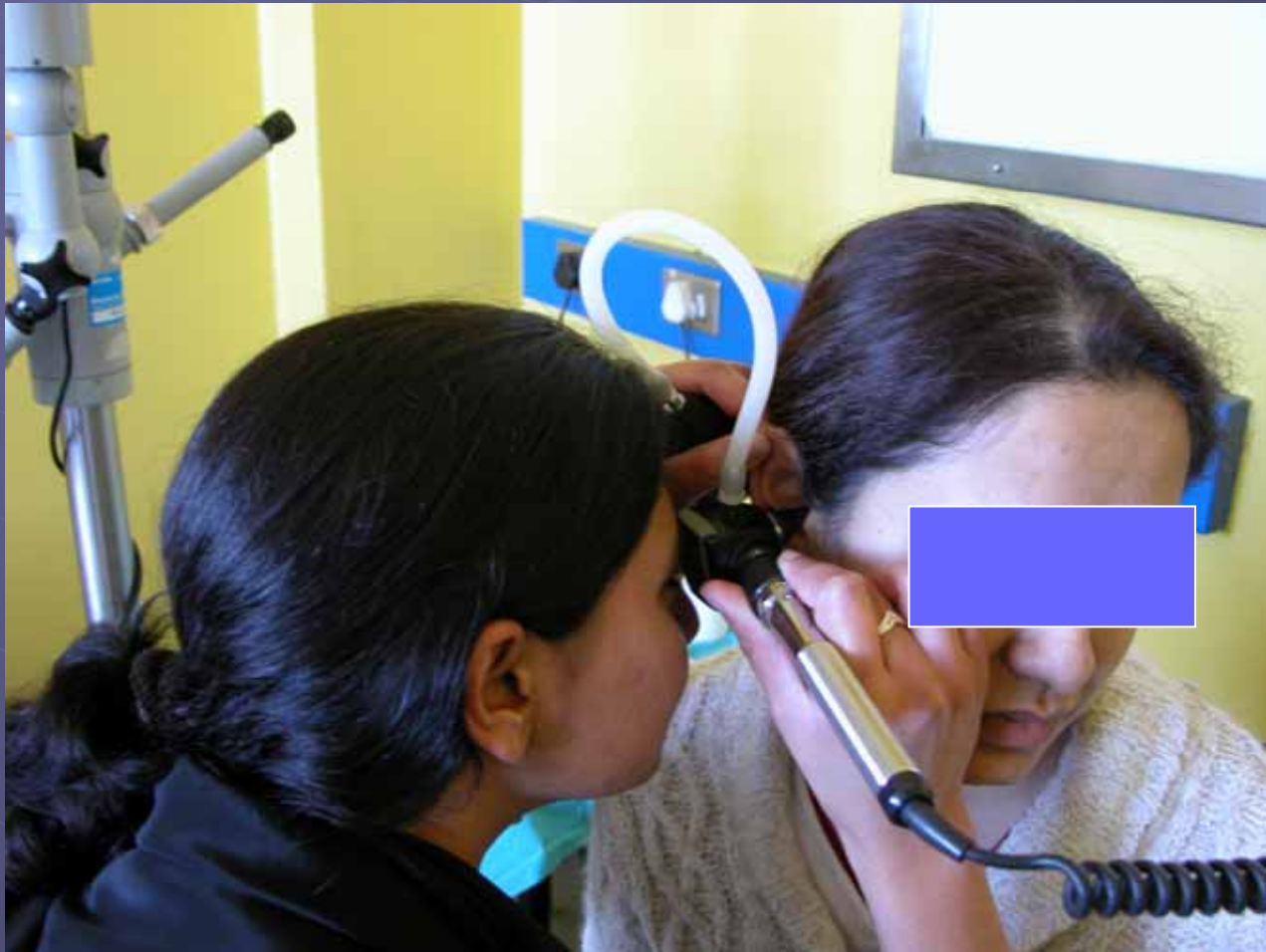

Signs of OME:

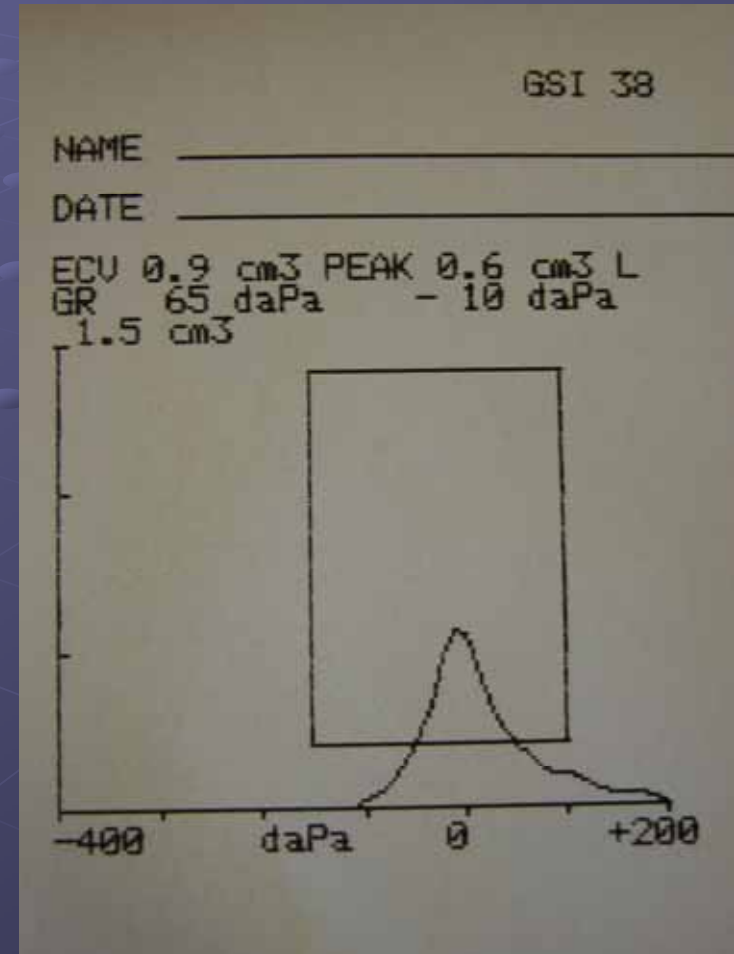
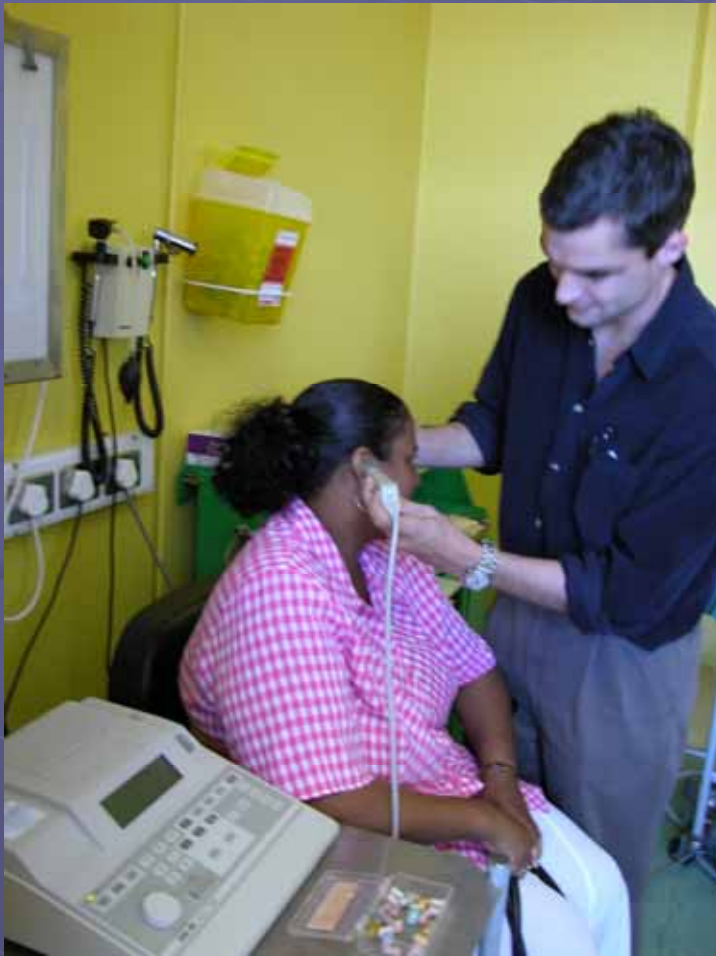- TM inflamed (a bit)
- Air-fluid level



Pneumatic Otoscopy:



Tympanometry:



Consequences of OME:

- Moderate conductive hearing loss
- Speech delay
- ? Anatomical changes of eardrum longterm?
- ? Recurrent otitis media
- ? Maternal insomnia

Natural history of OME :

● ~ 50 % resolve in 2 months

Treatment of OME:

- Reassure and wait
- Grommets
- ?Hearing aids???

